



PATIENT

Milo ONeill

SPECIES

Canine

BREED

Maltese Mix

SEX

MN

AGE

12

WEIGHT

9.2

INTERPRETED BY

R. McKenzie Daniel,
DVM, DABVP
(Canine and Feline)

IMAGING PERFORMED BY

Jenn

HOSPITAL NAME

Rockaway Animal
Hospital

REFERRING VET

Dr Maniar

INVOICE

24842

DATE

05/14/2026

PRESENTING CLINICAL SIGNS

Increased thirst for 3 week , sleeping more , O thinks dog dog has gained weight Current meds Denamarin

Abnormal PE/Chem/CBC/UA Results: WNL

ULTRASONOGRAPHIC EXAMINATION OF THE ABDOMEN

Urinary System

The urinary bladder, trigone, cystourethral junction, and visible pelvic urethra to a depth of 3 cm exhibited normal thickness and tone. Anechoic urine was present in the lumen with no evidence of urine/lumen sediment, mineral, or calculi. The ureteral papillae were normal. The ureters were not visible which is normal. No evidence of inflammatory or neoplastic changes was noted.

Normal size and margination were present in the kidneys. A normal 1:3 cortex / medulla ratio was maintained. The medulla and cortices were uniform in texture with some increased echogenicity and mild loss of corticomedullary symmetry and definition expected for the age of the patient. No evidence of pelvic dilation was present. The left kidney measured 3.1 cm in length. The right kidney measured 3.6 cm in length.

The area of the aortic trifurcation was free of pathology.

The area of the residual prostate appeared normal and free of pathology.

Adrenal Glands

The left adrenal gland was uniform in size and contour with a uniformly hypoechoic parenchyma. The left adrenal gland measured 0.43 cm width at the caudal pole. The right adrenal gland was uniform in size and contour with a uniformly hypoechoic parenchyma. The right adrenal gland measured 0.45 cm width at the caudal pole.

Spleen

The spleen exhibited a finely textured and homogenous parenchyma which was hyperechoic to the liver and renal cortical parenchyma. The capsule was smooth and regular without apparent expansion. The splenic vasculature at the hilus was normal in volume with no evidence of congestion or thrombosis. Acute to chronic inflammatory, neoplastic, or benign parenchyma changes were not noted.

Liver/Gallbladder

The liver was subjectively normal in size, structure, and contour. The liver parenchyma was uniform and hypoechoic to the spleen with a mild coarse echotexture. Normal vascular volume. The hepatic and portal vasculature were normal in appearance without signs of congestion. The gallbladder was non-distended in size with thin walls and mild non-organized debris. The cystic and common bile ducts were normal.

Gastrointestinal

The stomach presented intact wall layering with a normal wall layer ratio. The lumen of the stomach contained mild non-shadowing ingesta sonographically suggestive of food echogenicity with no signs of obstruction or foreign material.



PATIENT

Milo ONeill

The small intestine presented intact wall layering with 1:3 muscularis/mucosa ratio. The lumen of the small intestine contained segmental similar appearing non-shadowing ingesta/chyme with no signs of obstruction or foreign material.

Normal visible colon wall layers were present with apparent formed feces in lumen.

SPECIES

Canine

Pancreas

The parenchyma of the left limb, body and right limb of the pancreas presented isoechoic to the adjacent omental fat. A normal curvilinear capsule contour of the pancreas was present. The visible pancreatic duct was normal. No signs of active inflammation or neoplastic disease was evident.

BREED

Maltese Mix

Free Abdomen

No omental masses, overt lymphadenopathy or peritoneal effusion was present.

SEX

MN

ULTRASONOGRAPHIC FINDINGS

Primary

AGE

12

- Mild chronic renal changes
- Normal adrenal glands
- Normal volume liver
- Mild gallbladder debris (non-mucocele)
- Gastrointestinal ingesta-consistent with food echogenicity

WEIGHT

9.2

INTERPRETATION OF THE FINDINGS & FURTHER RECOMMENDATIONS

No evidence of significant or definitive visceral pathology as an obvious contributing factor to the patient's clinical signs. No evidence of hepatic or adrenal pathology. Given reported normal lab work, monitoring of renal /hepatic parameters and UA is recommended.

Three view chest radiographs may be considered if not done to assess for occult thoracic pathology.

INTERPRETED BY

R. McKenzie Daniel,
DVM, DABVP
(Canine and Feline)

IMAGING PERFORMED BY

Jenn

HOSPITAL NAME

Rockaway Animal
Hospital

REFERRING VET

Dr Maniar

INVOICE

24842

DATE

05/14/2026



PATIENT

Milo ONeill

SPECIES

Canine

BREED

Maltese Mix

SEX

MN

AGE

12

WEIGHT

9.2

INTERPRETED BY

R. McKenzie Daniel,
DVM, DABVP
(Canine and Feline)

IMAGING PERFORMED BY

Jenn

HOSPITAL NAME

Rockaway Animal
Hospital

REFERRING VET

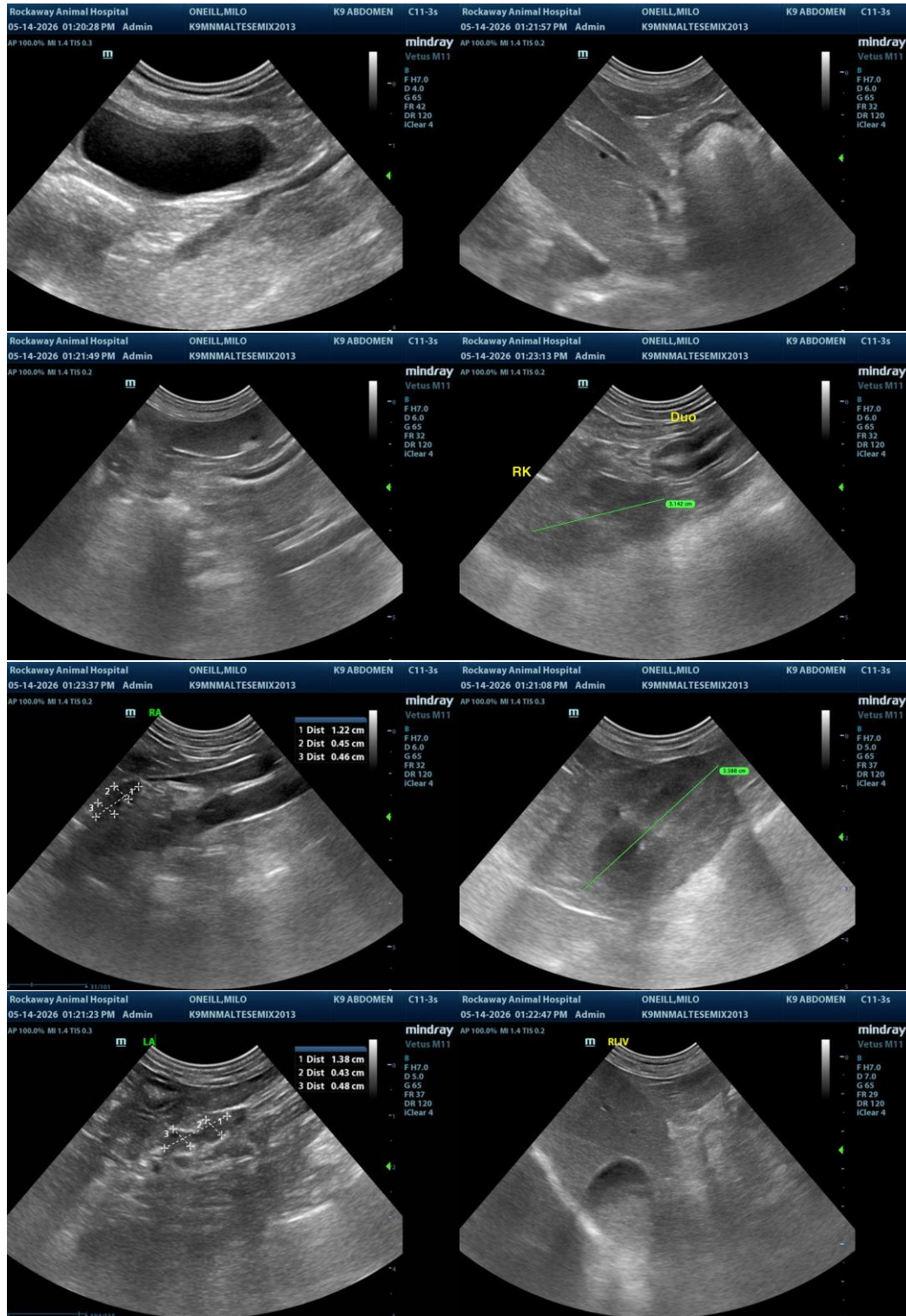
Dr Maniar

INVOICE

24842

DATE

05/14/2026



The information and recommendations provided are based on the images presented by the referring veterinarian/sonographer. No evaluation can be communicated regarding pathology that was not



PATIENT

Milo ONeill

visible in the image/video clips provided.

Thank you for this referral. If the clinical or image interpretation does not parallel your findings or if I can be of any further assistance, please contact me.

SPECIES

Canine

R. McKenzie Daniel, DVM, DABVP (Canine/Feline Practice)
info@sonopath.com

BREED

Maltese Mix

SEX

MN

AGE

12

WEIGHT

9.2

INTERPRETED BY

R. McKenzie Daniel,
DVM, DABVP
(Canine and Feline)

IMAGING PERFORMED BY

Jenn

HOSPITAL NAME

Rockaway Animal
Hospital

REFERRING VET

Dr Maniar

INVOICE 24842

DATE
05/14/2026